

EDR37 207334

A Riba

1	APPARENT MODE ACCIDENT	CASE NO 2013-04353
	SPECIAL CIRCUMSTANCES Media Interest	CRYPT 475

LAST, FIRST MIDDLE DOE #117, JOHN	AKA <i>JOE HASTINGS, Michael White</i>	# 117
---	---	--------------

ADDRESS	CITY	STATE	ZIP
---------	------	-------	-----

SEX MALE	RACE APPEARS CAUCASIAN	DOB <i>6/18/78</i>	AGE <i>33</i>	HGT 63 in.	WGT 140 lbs.	EYES UNKNOWN	HAIR UNKNOWN	TEETH ALL NATURAL TEETH	FACIAL HAIR NONE	ID VIEW No	CONDITION CHARRED
--------------------	----------------------------------	-----------------------	------------------	----------------------	------------------------	------------------------	------------------------	-----------------------------------	----------------------------	----------------------	-----------------------------

MARK TYPE	MARK LOCATION	MARK DESCRIPTION
-----------	---------------	------------------

NOK PENDING POSITIVE ID	ADDRESS	CITY	STATE	ZIP
-----------------------------------	---------	------	-------	-----

RELATIONSHIP	PHONE	NOTIFIED BY SELENA BARROS	DATE 6/18/2013	TIME 08:30
--------------	-------	-------------------------------------	--------------------------	----------------------

SSN	DL ID	STATE	PENDING BY
-----	-------	-------	------------

ID METHOD

LA #	MAIN #	CH #	FBI #	MILITARY #	POB
------	--------	------	-------	------------	-----

IDENTIFIED BY NAME (PRINT)	RELATIONSHIP	PHONE	DATE	TIME
----------------------------	--------------	-------	------	------

PLACE OF DEATH / PLACE FOUND STREET	ADDRESS OR LOCATION N HIGHLAND AVE, S/O MELROSE AVE	CITY LOS ANGELES	ZIP 90036
---	---	----------------------------	---------------------

PLACE OF INJURY STREET	AT WORK No	DATE 6/18/2013	TIME 04:20	LOCATION OR ADDRESS N HIGHLAND AVE, S/O MELROSE AVE, LOS ANGELES, C	ZIP 90036
----------------------------------	----------------------	--------------------------	----------------------	---	---------------------

DOD 6/18/2013	TIME 04:35	FOUND OR PRONOUNCED BY LAFD/ RA 052, P/M RODRIGUEZ
-------------------------	----------------------	--

OTHER AGENCY INV. OFFICER LAPD WEST TRAFFIC DIVISION - DET WHITE	PHONE (213) 473-0234	REPORT NO. 013-0618000581	NOTIFIED BY	NO
--	--------------------------------	-------------------------------------	-------------	----

TRANSPORTED BY TAMI AQUE	TO LOS ANGELES FSC	DATE 6/18/2013	TIME 08:10
------------------------------------	------------------------------	--------------------------	----------------------

FINGERPRINTS? Yes	CLOTHING Yes	PA RPT No	MORTUARY
MED. EV. No	INVEST. PHOTO # 48	SEAL TYPE NOT SEALED	HOSP RPT No
PHYS. EV. No	EVIDENCE LOG No	PROPERTY? Yes	HOSP CHART No
SUICIDE NOTE No	GSR NO	RCPT. NO. 267403	PF NO.

SYNOPSIS
 * AUTO (DRIVER) VS FIXED OBJECT (TREE), VEHICLE CAUGHT FIRE - PRONOUNCED AT SCENE. ON THE EARLY AM OF 06/18/13 AT ~0420 HRS, THIS ~33-YR OLD MALE (JOHN DOE D/T CHARRING) HAD BEEN TRAVELING S/B ON HIGHLAND AVE, S/O MELROSE AVE IN L.A., AT A HIGH RATE OF SPEED, WHEN HE APPARENTLY LOST CONTROL OF HIS VEHICLE COLLIDING W/ A TREE HEAD-ON. THE TREE WAS LOCATED ON A GRASS CENTER MEDIAN LOCATED IN A RESIDENTIAL AREA. SOCIAL HX INCLUDED POLYSUBSTANCE USE, W/ REPORT DECEDENT HAD BEEN SMOKING MARIJUANA THE NIGHT PRIOR. HE WAS ALSO BELIEVED AS USING DMT (HALLUCINOGENIC). FAMILY HAD JUST ARRIVED FROM NEW YORK THE DAY PRIOR, ATTEMPTING TO GET DECEDENT TO GO TO REHAB ...

SELENA BARROS 446970	<i>Sen Bar</i> INVESTIGATOR	DATE 6/19/2013	REVIEWED BY <i>JB</i>	DATE 6/20/13
-------------------------	-----------------------------	--------------------------	--------------------------	------------------------

FORM #3 NARRATIVE TO FOLLOW?



County of Los Angeles, Department of Coroner Investigator's Narrative



Case Number: 2013-04353

Decedent: DOE, JOHN # 117

Information Sources:

- Detectives Johnson # 34105 and White # 30194, LAPD- West Traffic Division, (213) 473-0234
- .

Investigation:

On 06/18/13 at approximately 0452 hours, a call was received from Officer Jeter # 30513 with LAPD- West Traffic Division, reporting the death of an unidentified male, who was involved in an 'auto vs. tree' collision. He was pronounced at scene. Assigned the investigation by Lieutenant MacWillie, I arrived on scene at 0535 hours, departing at 0725.

Location:

Street: N Highland Ave, s/o Melrose Ave, Los Angeles, CA 90036

Informant/Witness Statements:

In speaking with Detectives Johnson and White, the following information was learned: On the early morning of 06/18/13 at approximately 0420 hours, decedent had been traveling southbound on Highland Ave at a high rate of speed at the above-indicated location, when he apparently lost control of his vehicle colliding with a tree head-on in a center grass median. The vehicle caught fire. With EMS personnel summoned, responding LAFD extinguished the fire, with Rescue 52 Paramedic Rodriguez having pronounced decedent at scene at 0435 hours. Decedent was found seated in the driver's seat and due to extensive vehicular damage, would require LAFD extrication. The vehicle was reported as a silver 2013 Mercedes C25, with decedent and 'Daimler Trust' indicated as r/o of the vehicle; the vehicle appeared to have 'paper plates,' with the license plate number reported as 6ZGW914 (CA), VIN # WDDGJ4HB3DG058566. The posted speed limit at the location is 35-mph.

Tire marks were observed in the # 2 lane of Highland Ave, south of Melrose, which trailed off in an eastern direction toward the center grass median, with additional tire marks observed in the grassy area, which then trailed toward the tree which decedent ultimately collided with. A couple of alcohol bottles, unknown if belonged to decedent, were found strewn in the grassy area, north of the vehicle. Vehicular debris was spread over both sides of the street/ south and northbound traffic lanes, including the center median, with decedent's engine found near the next intersection south- located on the sidewalk area near the northeast corner of Highland and Clinton St; one of his wheels was found in the grassy center median past Clinton St- measurements pending at this time. The incident was captured on video, possibly (2) different videos, further information pending at this time.

Clearing from scene, Detective White and I responded to decedent's last known address per his found CDL. While at the residence, decedent's _____ arrived at about 0830 hours, having learned we were attempting family contact through the residence landlord – _____ had been staying at a neighboring residence. Per _____ he had just arrived from New York the day prior with another brother scheduled to arrive later this same morning, 06/18/13, as the family was attempting to get decedent to go to detox. Decedent was believed as "sober" for about the past 14-years, with _____ believing decedent had started to use drugs again the past month or so. He said decedent moved from NY to CA about a couple of months ago. He did not have any known medical problems. Upon inquiry, _____ believed decedent was currently using DMT (hallucinogenic), confirming use of 'medicinal marijuana' as well- ID card found in decedent's wallet. The medicinal marijuana was believed as prescribed for PTSD, as decedent was a war journalist, having had assignments in Iraq, Afghanistan, and in Baghdad a few years ago. There was also mention of a past traffic collision in which decedent



County of Los Angeles, Department of Coroner Investigator's Narrative



Case Number: 2013-04353

Decedent: DOE, JOHN # 117

collided into a pole several years ago, believed as under the influence at the time, with report decedent had been misusing Ritalin at about this time; at one point, he was believed to have been bi-polar; however, it was later learned his behavior was actually stemming from the Ritalin misuse. He was ultimately institutionalized for rehabilitative care in ~1999. Upon inquiry, decedent's history was not known to include any past suicide attempt/s or ideation/s; however, added decedent believed he was "invincible," believing he could jump from a balcony and would be okay. He added he would not be surprised if any stimulants were found within the residence, including cocaine.

Upon inquiry, said he had last seen decedent a few hours prior at decedent's residence sometime at about 0030 to 0100 hours, at which time decedent reportedly "passed out." Hence, left to stay at a neighboring residence, until contacted by the property landlord that Detective White and I were attempting family contact; he subsequently returned to the residence, at which time he was notified of decedent's demise. He had no idea where decedent may have been traveling to or from at the time of the collision, reporting decedent worked from home as he was a writer. Upon inquiry, decedent had been smoking marijuana the night prior, with no known alcohol consumption at the time.

Scene Description:

The scene was a residential-type street, where decedent's vehicle was observed partially resting atop the grass center median, facing in a southeastern direction. The front end area was slightly wrapped around the tree, with the rear tires hanging off the edge of the curb resting into the # 1 lane of southbound traffic. Tire marks were observed in the # 2 lane of southbound traffic, south of Melrose Ave, which trailed in a southeastern direction leading toward the grass center median were additional apparent tire marks were observed, which then trailed toward the involved tree. Vehicular debris was observed in the surrounding area about both sides of the street, particularly south of the vehicle, with debris observed in all directions. Decedent's vehicle came to rest in about the middle area between Melrose Ave and Clinton St, with decedent's engine block observed near the Clinton St intersection – measurements pending by LAPD. The vehicle was charred. A couple of apparent empty alcohol bottles were observed in the grassy median, observed north of the vehicle, located at least ~15+ feet away or so.

Evidence:

None collected

Body Examination:

Decedent was observed seated inside his extremely damaged/ charred vehicle, appearing his seat had been pushed back about a couple of feet or so. He was slumped forward, leaning toward his left; as he was well wedged into the vehicle, he required LAFD extrication. During extrication, LAFD/ Station 27 Firefighter Cooper noted decedent had been a restrained driver. Once extricated which took approximately ½ hour, decedent was then placed onto sheet and plastic next to his vehicle. He was charred, unidentifiable; the charring was observed primarily to his head/ neck, upper chest and back, and to the left side of his body. His clothing was severely burned, with decedent appearing to have worn a blue shirt and brown pants, with a white sock and black/ gray tennis shoe observed to the left foot – the toes could be seen from the bottom of the shoe due to burning effect. An obvious skull fracture was observed at the top skull region, with decedent's tongue protruded, noted clenched between the teeth. Skin slippage was observed primarily to the right side of the body. Obvious open fractures were also observed to the right arm and both lower extremities. Decedent's wallet (intact) was found in his rear pants pocket, assisting in tentative identification. Due to body condition, neither livor nor rigor mortis were observed, with algor mortis not recorded as time of death not an issue.



County of Los Angeles, Department of Coroner
Investigator's Narrative



Case Number: 2013-04353

Decedent: DOE, JOHN # 117

Identification:

Due to charring, decedent was unidentifiable. He is believed to be 'Michael Mahon Hastings,' with a DOB of 01/28/1980.

Next of Kin Notification:

family the same date, 06/18/13. *was tentatively notified of decedent's demise via*

Tissue Donation:

Not a viable candidate- body condition

Autopsy Notification:

None requested

SELENA BARROS #4460970
SELENA BARROS

JOSEPH BALE
JOSEPH BALE

06-19-13
Date of Report


12

AUTOPSY REPORT

No.

2013-04353

HASTINGS, MICHAEL MAHON

I performed an autopsy on the body of 
 at the DEPARTMENT OF CORONER

Los Angeles, California

on JUNE 20, 2013 @ 0800 HOURS

(Date)

(Time)

From the anatomic findings and pertinent history I ascribe the death to:

(A) **TRAUMATIC INJURIES**

DUE TO, OR AS A CONSEQUENCE OF

(B)

DUE TO, OR AS A CONSEQUENCE OF

(C)

DUE TO, OR AS A CONSEQUENCE OF

(D)

OTHER CONDITIONS CONTRIBUTING BUT NOT RELATED TO THE IMMEDIATE CAUSE OF DEATH:

Anatomical Summary:

33-year-old white male collided with a tree. Pronounced dead at the scene.

Partially charred remains; heavily charred over the head, moderately over the neck and left side of body, left extremities, with postmortem thermal fracturing of the left forearm and left lower leg and foot.

Traumatic antemortem fractures of the right arm, right forearm, and right femur.

Hemorrhagic displaced fracture of the right greater horn of the hyoid bone.

Hemorrhagic fractures of the left anterior 3rd through 8th ribs.

Anterior lung contusions, purple, bilateral.

Massive bilateral bright red traumatic hemothorax, 450 cc left, 400 cc right.

Extensive laceration of the parietal pericardium and mediastinal pleura.

Avulsion of the base of the heart with complete transverse avulsion of the atria and superior and inferior vena cava. 7 cm hemorrhagic laceration of the apex of the left ventricle.

12**AUTOPSY REPORT**

No.

2013-04353

HASTINGS, MICHAEL MAHON

Page 2

Hemorrhagic traumatic transection of the descending thoracic aorta at T-6.

Massive complex lacerations of the liver, extending all the way through.

Displaced pelvic fracture with torn urinary bladder.

Massive displaced modified ring-type basal skull fracture with lacerations of the base of the brain. Protrusion of the cervical vertebral column into the cranial vault. Focal subarachnoid hemorrhage, minimal.

Please see separate toxicology report.

EXTERNAL DESCRIPTION:

The body is that of a white male with moderate charring. The charring is over the left side of the body while on much of the right side of the body the skin is white and pale. I don't see any tattoos, scars or identifying marks. The clothing with the body is consisting of upper body garments which are all torn up and just lying on top of the body and the right half of a pair of trousers which are still on the right leg. Also some sneakers. Much of the clothing is burned up.

There is heavy charring of the entire head and neck and the scalp over the calvaria is completely burned off. The face is unrecognizable and completely charred. The eyes are cooked. The tongue protrudes and is thoroughly blackened. There is moderate charring over the neck and left shoulder area, front and back and down the left side of the back, entire left upper and lower extremities. The left upper extremity has pugilistic posture with thermal fracturing of the wrist and hand. The left lower extremity has thermal fracturing of the lower leg and foot. Native teeth are present in the oral cavity.

12**AUTOPSY REPORT**

No.

2013-04353

HASTINGS, MICHAEL MAHON

Page 3

EXTERNAL EVIDENCE OF TRAUMA:

The calvaria has a displaced fracture of the skull extending from the right brow down to the left inferior occipital area. There is a displaced fracture of the proximal right humerus and a displaced fracture of the mid shaft of the right radius and ulna and a displaced fracture of the right femur and also of the right lower leg.

PRIMARY INCISION:

A Y-shaped incision is used to enter the body cavities. We find considerable cooking of the skin, the subcutaneous tissue, the muscles and fascia of the neck and left side of the shoulder and left abdomen and of the left chest. There is no blood or fluid in the peritoneal cavity and no adhesions.

The rib cage shows inwardly displaced hemorrhagic fractures of the left anterior 3rd through 8th ribs. Opening the chest reveals a large bright red liquid bilateral traumatic hemothorax, 450 cc left and 400 cc right. Samples of this are collected for toxicology in the glass NaF bottle and by reverse vacuum aspiration by needle into the purple-top tube, both labeled "chest blood." Further exploration of the chest discovers extensive hemorrhagic laceration of the parietal pericardium and bilateral mediastinal pleura.

Neck dissection finds hemorrhagic displaced fracture of the right greater horn of the hyoid. Prevertebral fascia hemorrhage is not found.

CARDIOVASCULAR SYSTEM:

As noted above, the parietal pericardium is extensively torn. The heart is empty of blood and is found to have traumatic avulsion of the base of the heart with transaction of the superior and inferior vena cava at their attachments to the heart. The aorta and pulmonary artery are still attached. There is a hemorrhagic 7 cm anterior full-thickness laceration of the apex of the left ventricle. The coronary arteries are free of plaque. The

12**AUTOPSY REPORT**

No.

2013-04353

HASTINGS, MICHAEL MAHON

Page 4

myocardium is firm and red. There are no mural or valvular abnormalities. The heart weight is 250 grams. Exploring the aorta, we find a complete hemorrhagic transection of the descending thoracic aorta at the T-6 vertebral level. The great vessels are empty of blood.

RESPIRATORY SYSTEM:

The lungs are well inflated and light pale fluffy. There are focal purple contusions on the anterior aspects of both lungs. The right lung weighs 250 grams and the left lung 200 grams. The bronchi and pulmonary arteries are intact and empty. The lungs are bloodless. The visceral pleura is intact, smooth, and without adhesions.

GASTROINTESTINAL SYSTEM:

The esophagus has extensive periesophageal hemorrhage (traumatic hemomediastinum). The stomach is intact and contains 10 cc of pale tan fluid (not collected). The small intestine is pale and anemic, as is the large intestine. They have normal light-colored content. The appendix is present. The mesentery has no tears or hemorrhages.

HEPATOBIILIARY SYSTEM:

The liver has multiple through-and-through lacerations in the horizontal dimension, with minimal hemorrhage. The organ is smooth and red and weighs 1300 grams. The gallbladder is present and is intact and contains about 25 cc of bile, a sample of which is collected for toxicology by reverse needle vacuum aspiration into a gray-top tube. Liver tissue is also collected. The bile ducts and pancreas are normal.

12**AUTOPSY REPORT**

No.

2013-04353

HASTINGS, MICHAEL MAHON

5

Page _____

URINARY SYSTEM:

The kidneys are smooth and very pale pink anemic, and occupy a normal position in the retroperitoneum, the right kidney weighing 150 grams and the left kidney 150 grams. They have no injury. Their interior architecture as examined by bivalve dissection is unremarkable. The ureters follow a normal course to the bladder. The urinary bladder is extensively torn.

GENITAL SYSTEM:

The prostate gland is unremarkable. The testicles are atraumatic.

HEMATOPOIETIC SYSTEM:

The spleen is intact and weighs 150 grams. It is bloodless. The bone marrow is red.

ENDOCRINE SYSTEM:

The pituitary gland, thyroid gland, and adrenal glands are unremarkable.

CENTRAL NERVOUS SYSTEM:

The scalp is charred throughout. There is an open displaced fracture of the left frontal bone in the forehead area. Opening the skull reveals thin subarachnoid hemorrhage over the base of the brain, with extensive laceration of the base of the brain associated with a markedly displaced ring-type basal skull fracture with protrusion of the cervical vertebral column into the cranial vault and avulsion of the brain stem and cervical spinal cord.

There is no subdural or parenchymal brain hemorrhage. Other than thin subarachnoid hemorrhage, there is no blood in the cranial cavity or dura mater.

12**AUTOPSY REPORT**

No.

2013-04353

HASTINGS, MICHAEL MAHON

Page 6**MUSCULOSKELETAL SYSTEM:**

There is an open fracture of the forehead, a displaced ring-type basal skull fracture, postmortem thermal fracturing of the left forearm and left lower leg, traumatic fractures of the right humerus, right forearm, pelvis, and right femur. The pelvis has a widely displaced fracture of the pubic symphysis with bladder laceration and also a displaced fracture of the posterior pelvis with pelvic hematoma.

TOXICOLOGY:

I collected chest blood in a NaF blood jar and in a purple-top tube. I collected bile, liver and brain tissue. A comprehensive screen is asked for, along with MDA. Please see separate toxicology report.

HISTOLOGY:

Representative sections of all organs are collected in one can of formalin.

WITNESSES:

None.

OPINION:

The cause of death was massive blunt force trauma consistent with a high speed front-end impact to the sole of the right foot and to the front of the torso. There was transmission of force superiorly through the right foot and leg, pelvis and vertebral column into the head. There was also severe impact to the anterior chest and upper abdomen with resulting rib fractures and anterior displacement of the heart and upper thoracic aorta (deceleration injury). Death was very rapid, within seconds. Loss of consciousness was likely instantaneous upon impact.

12**AUTOPSY REPORT**

No.


2013-04353

HASTINGS, MICHAEL MAHON

Page 7

Toxicology shows a small amount of amphetamine in the blood, consistent with possible intake of methamphetamine many hours before death, unlikely to have an intoxicative effect at the time of the accident. Marijuana was present in the blood, but mostly in the form of its metabolite, indicating intake hours earlier. All other drugs were negative.

The carbon monoxide level in the chest blood was below 10 volumes percent, indicating that decedent did not inhale products of combustion, consistent with an instantaneous death. The burns are entirely postmortem.



JAMES K. RIBE, M.D.
SENIOR DEPUTY MEDICAL EXAMINER

8 . 20 . 13
DATE

JKR:bbtt/sp
D:06/20/13
T:07/01/13

15

AUTOPSY CLASS: A B C Examination Only D

FAMILY OBJECTION TO AUTOPSY

Date: 6.20.13 Time: 8:00 Dr. RIBE
(Print)

FINAL ON: 8.16.13 By: RIBE
(Print)

APPROXIMATE INTERVAL BETWEEN ONSET AND DEATH

2013-04353
CASTINGS, MICHAEL R
ACC

475

DEATH WAS CAUSED BY: (Enter only one cause per line for A, B, C, and D)

IMMEDIATE CAUSE:

(A) TRAUMATIC INJURIES
DUE TO, OR AS A CONSEQUENCE OF:

(B)
DUE TO, OR AS A CONSEQUENCE OF:

(D)
DUE TO, OR AS A CONSEQUENCE OF:

OTHER CONDITIONS CONTRIBUTING BUT NOT RELATED TO THE IMMEDIATE CAUSE OF DEATH:

Age: 33 Gender: Male / Female

PRIOR EXAMINATION REVIEW BY DME

- BODY TAG ASC CLOTHING
- X-RAY (No. _____) FLUORO
- SPECIAL PROCESSING TAG MED. RECORDS
- AT SCENE PHOTOS (No. _____)

CASE CIRCUMSTANCES

- EMBALMED
- DECOMPOSED
- >24 HRS IN HOSPITAL
- OTHER: _____ (Reason)

TYPING SPECIMEN

TYPING SPECIMEN TAKEN BY: R
SOURCE: CHEST

TOXICOLOGY SPECIMEN

- COLLECTED BY: R
- HEART BLOOD STOMACH CONTENTS
 - FEMORAL BLOOD VITREOUS
- TECHNIQUE:
- CHEST BLOOD SPLEEN
 - BLOOD KIDNEY
 - BRAIN
 - LIVER
 - URINE

URINE GLUCOSE DIPSTICK RESULT: 4+ 3+ 2+ 1+ 0
TOX SPECIMEN RECONCILIATION BY: AS

HISTOLOGY

Regular (No. ()) Oversize (No. _____)
Histopath Cut: Autopsy Lab

TOXICOLOGY REQUESTS

- FORM 3A: YES NO
- NO TOXICOLOGY REQUESTED
 - SCREEN C H T S D
 - ALCOHOL ONLY
 - CARBON MONOXIDE
 - OTHER (Specify drug and tissue)
MDA, Ritalin

REQUESTED MATERIAL ON PENDING CASES

- POLICE REPORT MED HISTORY
- TOX FOR COD HISTOLOGY
- TOX FOR R/O INVESTIGATIONS
- MICROBIOLOGY EYE PATH. CONS.
- RADIOLOGY CONS.
- CONSULT ON: _____
- BRAIN SUBMITTED
- NEURO CONSULT DME TO CUT
- CRIMINALISTICS
- GSR SEXUAL ASSAULT OTHER

- NATURAL SUICIDE HOMICIDE
- ACCIDENT COULD NOT BE DETERMINED

If other than natural causes,
HOW DID INJURY OCCUR? AUTO (DRIVER) VS. FIXED OBJECT

WAS OPERATION PERFORMED FOR ANY CONDITION STATED ABOVE: YES NO

TYPE OF SURGERY: _____ DATE: _____

- ORGAN PROCUREMENT TECHNICIAN: _____
- PREGNANCY IN LAST YEAR YES NO UNK NOT APPLICABLE
- WITNESS TO AUTOPSY EVIDENCE RECOVERED AT AUTOPSY
Item Description: _____

Autopsy Report dictated 6.20.13 JER

RESIDENT _____ DME [Signature]

16

2013-04353
TARRANTS, MICHAEL M
ALL

475

EXTERNAL EXAM

Sex M
Race C
Age 33
Height
Weight
Hair
Eyes
Sclera
Teeth
Mouth
Tongue
Nose
Chest
Breasts
Abdomen
Scar
Genitals
Edema
Skin
Decubitus

HEART Wt. 250
Pericardium inc RV
Hypertrophy Septum
Dilation LV
Muscle inc Septum
Valves
Coronaries

AORTA transec T-6

VESSELS

LUNGS Wt.
R 250
L 200

Adhesions
Fluid + + +
Atelectasis
Oedema
Congestion
Consolidation
Bronchi
Nodes

PHARYNX
TRACHEA
THYROID
THYMUS
LARYNX
HYOID fx

ABDOMINAL WALL FAT 1/2"

PERITONEUM

Fluid
Adhesions

LIVER Wt. 1300

Capsule *fx*
Lobules *to u*
Fibros
G B present
Calculus *no*
Bile ducts

SPLEEN Wt. 150

Color
Consistency
Capsule
Malpiment

PANCREAS

ADRENALS

KIDNEYS Wt.

R 150
L 150

Capsule
Cortex
Vessels
Pelvis *blood*
Ureters

BLADDER *to u*

GENITALIA

Prostate
Testes
Uterus
Tubes
Ovaries

OESOPHAGUS *hemom*

STOMACH

Contents 10 cc *tan*

DUOD. & SM. INT.

APPENDIX *present*

LARGE INT.

ABDOM. NODES

SKELETON

Spine
Marrow *red*
Rib Cage *fx* *D*
Long bones
Pelvis *fx*

blank = normal or none

SCALP *bound off*

CALVARIUM *fx*

BRAIN Wt. 1400

Dura
Fluid
Ventricles
Vessels
Middle ears
Other

PITUITARY

SPINAL CORD

TOXICOLOGY SPECIMENS

blood bile liver brain EDTA

SECTIONS FOR HISTOPATHOLOGY

1 can

MICROBIOLOGY

DIAGRAMS 20
X-RAYS

OTHER PROCEDURES

GROSS IMPRESSIONS

no form 12

Date

6 - 20 - 13

Time

8:00

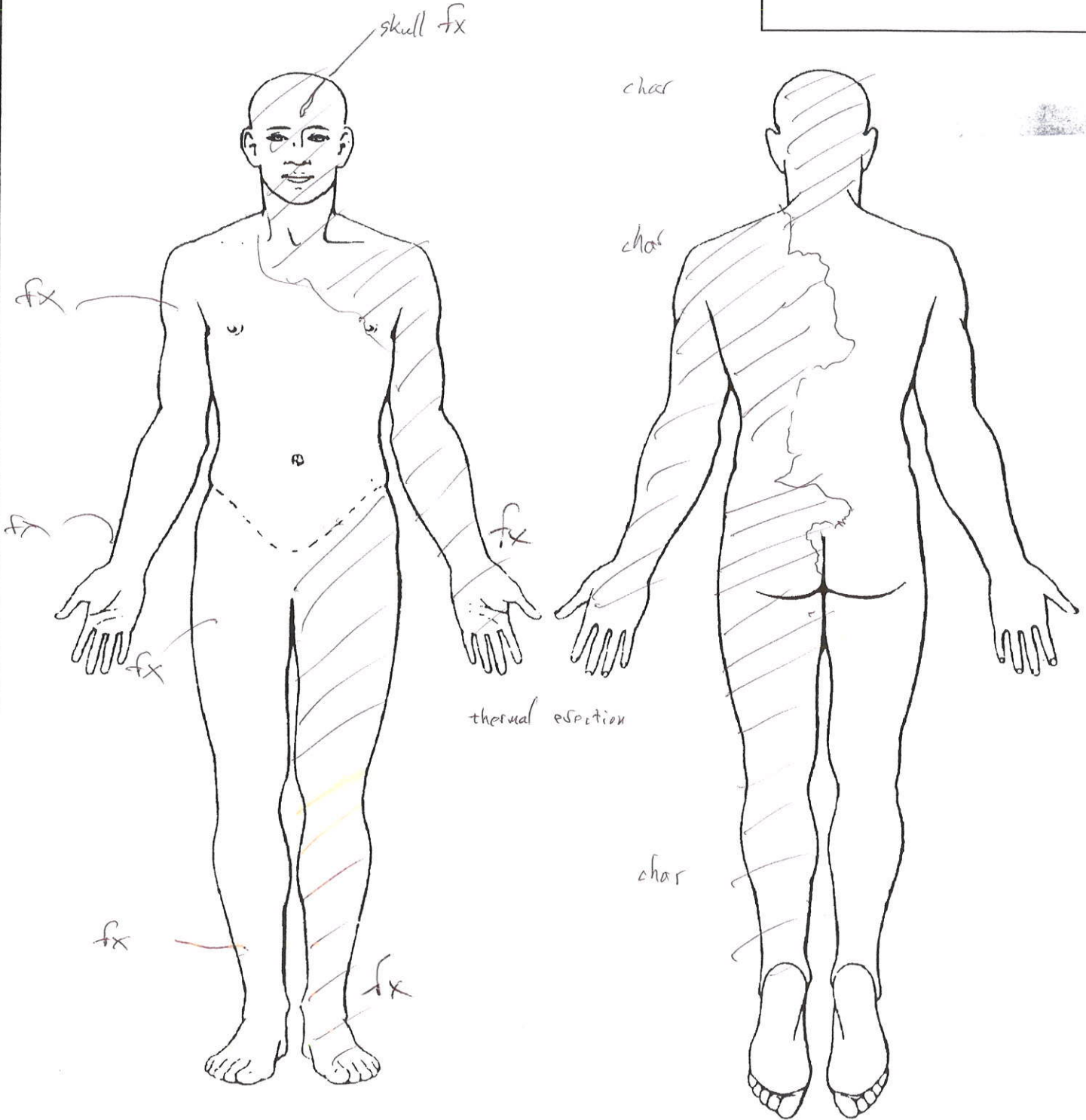
Deputy Medical Examiner

[Signature]

20

Charred white male

2013-04353
HASTINGS, MICHAEL M
ACC
475



burned up clothing

Date 6 20 17

[Signature] M.D.
Deputy Medical Examiner



Department of Coroner, County of Los Angeles
FORENSIC SCIENCE LABORATORIES
 1104 North Mission Road Los Angeles, CA 90033
Laboratory Analysis Summary Report



Ribe, James M.D.

Deputy Medical Examiner
 1104 North Mission Road
 Los Angeles, CA 90033

PendingTox

The following results have been technically and administratively reviewed and are the opinions and conclusions of the Analyst:

Coroner Case Number: 2013-04353 **Decedent:** HASTINGS, MICHAEL MAHON

<u>SPECIMEN</u>	<u>SERVICE</u>	<u>DRUG</u>	<u>RESULT</u>	<u>ANALYST</u>
Bile				
	Methamphetamine-GC/MS	Amphetamine	0.19 ug/mL	C. DalChele
Blood, Chest				
	Alcohol-GC/FID-HS	Ethanol	Negative	M. Schuchardt
	Bases-GC/NPD &/or MS	Methylphenidate	ND	C. Miller
	ELISA-Immunoassay	Barbiturates	ND	B. Ciullo
	ELISA-Immunoassay	Cocaine and Metabolites	ND	B. Ciullo
	ELISA-Immunoassay	Fentanyl	ND	B. Ciullo
	ELISA-Immunoassay	Methamphetamine & MDMA	ND	B. Ciullo
	ELISA-Immunoassay	Opiates: Codeine & Morphine	ND	B. Ciullo
	ELISA-Immunoassay	Opiates: Hydrocodone & Hydromorphone	ND	B. Ciullo
	ELISA-Immunoassay	Phencyclidine	ND	B. Ciullo
	LC/MS	Benzodiazepines	ND	J. Lintemoot
	Marijuana-GC/MS	Carboxy-THC, Total	154 ng/mL	C. DalChele
	Marijuana-GC/MS	Tetrahydrocannabinol (THC), Total	12 ng/mL	C. DalChele
	MDA-GC/MS	Methylenedioxyamphetamine	ND	C. DalChele
	Methamphetamine-GC/MS	Amphetamine	0.05 ug/mL	C. DalChele
	Outside Test	*	ND	NMS Labs, Inc.
EDTA Blood				
	Carbon Monoxide-UV/VIS	Carbon Monoxide	< 10 % Saturation	M. Schuchardt
Liver				
	Methamphetamine-GC/MS	Amphetamine	0.57 ug/g	C. DalChele

RECEIVED
 JKR
 8-16-13

Coroner Case Number: 2013-04353 **Decedent:** HASTINGS, MICHAEL MAHON

SPECIMEN **SERVICE** **DRUG** **RESULT** **ANALYST**

NOTE: *=Dimethyltryptamine (DMT). The source of the EDTA Blood is from the chest.

Legend:		mg/dL	Milligram per Deciliter	QNS	Quantity Not Sufficient
g	Grams	mg/L	Milligram per Liter	TNP	Test Not Performed
g%	Gram Percent	ND	Not Detected	ug	Micrograms
Inc.	Inconclusive	ng/g	Nanograms per Gram	ug/g	Micrograms per Gram
mg	Milligrams	ng/mL	Nanograms per Milliliter	ug/mL	Microgram per Milliliter

In accordance with the Department's Evidence Retention Policy, the blood specimen(s) will be retained for one-year and all other specimens for six-months from Autopsy.

Administratively reviewed by:

Daniel T. Anderson, M.S., FTS-ABFT, D-ABC
Supervising Criminalist II
TOXICOLOGY

(323) 343-0660 Danderson@coroner.lacounty.gov

JAB
8-16-13



NMS Labs

CONFIDENTIAL

3701 Welsh Road, PO Box 433A, Willow Grove, PA 19090-0437
Phone: (215) 657-4900 Fax: (215) 657-2972
e-mail: nms@nmslabs.com

Robert A. Middleberg, PhD, DABFT, DABCC-TC, Laboratory Director

Toxicology Report

Report Issued 08/10/2013 17:00

Patient Name HASTINGS, MICHAEL

Patient ID 2013-04353

Chain 11620427

Age Not Given Gender Not Given

10139

Los Angeles County Coroner Medical Examiner
Attn: Joseph Muto
1104 N. Mission Road
Los Angeles, CA 90033

Workorder 13192128

Received 08/06/2013 12:00

Chain of custody documentation has been maintained for the analyses performed by NMS Labs.

Unless alternate arrangements are made by you, the remainder of the submitted specimens will be discarded six (6) weeks from the date of this report; and generated data will be discarded five (5) years from the date the analyses were performed.

Sample ID 13192128-001

Matrix Blood

Patient Name HASTINGS, MICHAEL

Patient ID 2013-04353

Container Type Red Top Tube

Collect Dt/Tm 08/05/2013

Source Chest Blood

Approx Vol/Weight 4.5 mL

Receipt Notes None Entered

Table with 5 columns: Analysis and Comments, Result, Units, Reporting Limit, Notes

9156B Dimethyltryptamine Screen, Blood

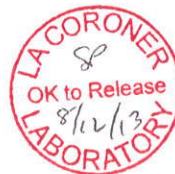Analysis by Gas Chromatography (GC)

Dimethyltryptamine None Detected ng/mL 5.0

Synonym(s): DMT; Component of Ayahuasca

Peak plasma concentrations ranged from 12 - 26 ng/mL (mean, 16 ng/mL) at 1.5 hours after a 29 mg oral dose of an herbal tea.

Pheniramine and phencyclidine interfere with dimethyltryptamine in this analysis. The presence of pheniramine and phencyclidine will adversely affect the quantitation of dimethyltryptamine. If pheniramine or phencyclidine are potential interferents in this case, call the laboratory for alternate quantitative procedures.



Handwritten signature and date: JKR 8.16.13